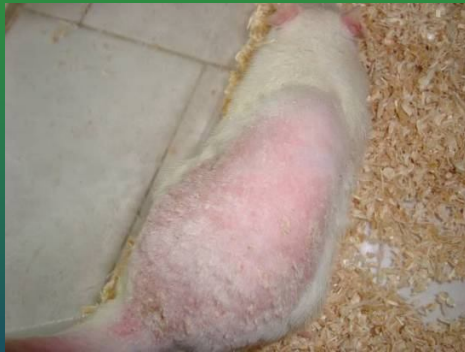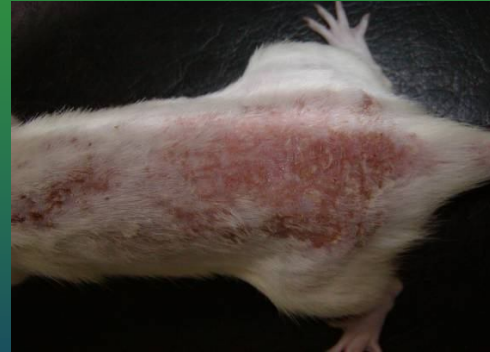


# SERS analysis of the skin tissue

After exposure to ultraviolet radiation, the skin manifests injury in a variety of ways, including both acute and chronic responses, the most evident acute feature of UV radiation exposure is erythema (redness or sunburn) Figure 1. After one month of exposure. The visual aspects indicated important skin damages that suggested photoaging and first steps of skin carcinoma.



A



B

Skin photodamage in evolution:

A. after 4 weeks (erythema)

B. After 10 weeks (carcinoma)